

Role of stereotactic biopsy in histological diagnosis of multiple brain lesions

Ali Meshkini, Sohrab Shahzadi¹, Hossein Alikhah², Mohammad Naghavi-Behzad²

Neuroscience Research Center, ²Medical Philosophy and History Research Center, Tabriz University of Medical Sciences, Tabriz, ¹Functional Neurosurgery and Stereotaxy Research Center, Shahid Beheshti Medical University, Tehran, Iran

ABSTRACT

Background and Aim: The current advances in diagnostic and therapeutic modalities and increasing in survival of patients with systemic diseases and immunosuppressive cases have caused to increasing frequency and variety of Central Nervous System neuropathologic processes indicating the necessary need for accurate localization of space-occupying lesions by cytology and histology. This study was aimed to evaluate the usefulness and safety of stereotactic biopsy in histological diagnosis of such lesions.

Materials and Methods: Of 2081 patients underwent stereotactic biopsy of brain lesions using Riechert-Mundinger system, 158 had multifocal brain lesions, and were enrolled.

Results: The ages of studied cases were ranged from 2 years to 75 years (Mean age: 41.3 year), 114 were male and 44 were females. Incidence of histopathologic diagnosis of multifocal brain lesions included Astrocytoma grade II (41.3%), Astrocytoma grade I (12.9%), glioblastoma multiform (11.1%), Astrocytoma grade III (10.2%), malignant lymphoma (10.2%), metastasis (4.6%), pilocytic Astrocytoma (2.7%), abscess (2.7%), craniopharyngioma (1.8%) vascular malformations (0.9%), and tuberculosis (0.9%). Mortality due to operation is none.

Conclusions: Histopathologic diagnosis of multiple brain lesions is necessary for decision of appropriate management and stereotactic biopsy of brain lesion is a useful and safe method for histological diagnosis.

Key words: Biopsy, brain, lesion, multifocal, stereotactic

Introduction

Now a days, the number of detections related to various brain lesions has increased using computed tomography (CT) scan and magnetic resonance imaging (MRI) for diagnosis of patients suffering from neurological focal deficiency or symptoms of increasing intracranial pressure or even for patients with slighter symptoms.^[1-4] Furthermore, advances in the therapeutic methods and increasing number of survival in patients with systematic diseases, resulted in the

developing of metastatic into the central nervous system or high incidence of CNS infections, which are partly due to high confrontation with immune system deficiency (due to Acquired Immunodeficiency Syndrome (AIDS) or following immunosuppressive treatment in the recipients of transplantation or in patients under chemotherapy for systematic cancer); diversity and the number of CNS neuro-pathologies has increased requiring the needs for the more accurate detailed differential diagnosis of histology and cytology of cerebral space-occupying lesions (SOLs).^[1-3,5-9]

However, in most of the patients, it is possible to show nature of their brain lesion, accurately through clinical and laboratory findings. Examples are multiple sclerosis, secondary infectious and parasite diseases, metastatic tumors and brain involvement of systemic disease. However, in some cases, numerous brain lesions that are diagnosed in CT scan or MRI are the only provable documents for the disease and a proper therapy designing depends on the histological diagnosis.^[3-5,10-15]

The main purpose of this paper is to show the benefits of stereotactic methods for diagnosing the nature of these lesions.

Access this article online

Quick Response Code:



Website:

www.asianjns.org

DOI:

10.4103/1793-5482.116374

Address for correspondence:

Dr. Mohammad Naghavi-Behzad, Medical Philosophy and History Research Center, Tabriz University of Medical Science, Daneshgah Street, Tabriz, Eastern Azerbaijan, Iran.
E-mail: dr.naghavii@gmail.com

Materials and Methods

This is a retrospective study performed on 2081 patients undergone stereotactic biopsy of brain lesions since 1989 until 2007, amongst them, 158 patients have had multiple brain lesions. The patients were selected for stereotactic biopsy, based on the following criteria:

1. An undiagnosed intra-axial mass lesion that could not be approved by standard craniotomy without undue risk of morbidity
2. Invasive lesions without significant mass effect
3. Poorly defined lesions on CT or MRI
4. An intracranial lesion in a patient whose general medical status precluded craniotomy
5. A condition for which medical therapy would likely be superior to operative resection (e.g., multiple lesions)
6. Differentiating between tumor recurrence and radionecrosis
7. Suspicion of lesions with significant radio-sensitivity such as lymphomas and germinoma
8. Lesions which are highly susceptible to non-neoplastic origin such as infections and demyelinating lesions; and
9. Patients with poor general medical conditions who could not tolerate general anesthesia and major surgery.

There were 114 male (72.2%) and 44 female patients (27.8%). The mean age of patients was 41.3 ± 15.9 years (range of 2-75 year). The most prevalent age period of disease was the fifth decade. According to accessibility to imaging tools and facilities, the patients underwent CT scan (with and without contrast), or MRI (with and without contrast). Furthermore, in some rare cases for the better judgment of lesions both methods were used. Multiple brain lesions were considered as two or more discrete lesions in multiple cerebral lobes, multi loculated lesions in multiple lobes, such as craniopharyngioma and diffuse involvement of brain in multiple lobes as seen in glioma. The number of the lesions was two or more. Fifty two patients had right hemisphere lesions and 86 had left hemisphere lesions and 20 had lesions in both hemispheres. All of the stereotactic biopsies were conducted using Riechert-Munding system and all of the samples were taken using biopsy needle and aspiration. No case of mortality was found.

Results

Histological diagnosis of lesions is summarized in Table 1. More than one fifth of the patients had multifocal malignant gliomas, including astrocytoma anaplastic (10.2%) and multiform glioblastoma (11.1%). More than half of the patients had low grade multifocal gliomas, and majority of them were distributed lesions that involved adjacent lobes. Numerous points of them had undergone enhancement so appeared as numerous multifocal lesions. Furthermore, 10.2% of the patients had malignant lymphoma, which have not responded to pre-operative corticosteroid. Of all patients, 4.6% had

Table 1: Histological diagnoses in 158 patients with multiple lesions made by stereotactic biopsy

Histological diagnosis	Percent
Astrocytoma pilocytic	2.7
Astrocytoma (grade I)	12.9
Astrocytoma (grade II)	41.6
Astrocytoma (grade III)	10.2
Multiform glioblastoma	11.1
Metastasis	4.6
Malignant lymphoma	10.2
Abscess	2.7
Craniopharyngioma	1.8
Vascular lesions (angiopathy)	0.9
Tuberculosis	0.9
Total	100

metastatic tumor, which didn't have any symptoms of primary tumor in any other part of their bodies prior to the biopsy. Furthermore, 2.7% of the patients had multiple brain abscesses with whom the intra abscess pus drainage was conducted beside the biopsy of abscess wall in order to help improvement of patients' clinical and neurological condition. There were some cases of the tuberculoma and multifocal vascular lesions in which the diagnosis was made only by brain biopsy despite performing several pre-operative analyses. Furthermore, 1.8% of cases had craniopharyngioma, where evacuation of cyst fluid, putting a reservoir for next drainages, and applying radioactive phosphorus were conducted in addition to tissue diagnosis.

Discussion

A vast range of diseases in this series of patients emphasize on the importance of lesion histology in order to avoid the risks of therapies based on the clinical and imaging data. Stereotactic biopsy with low morbidity and without mortality would fulfill this goal. In the analysis of Franzini *et al.*, among 940 patients, 100 (10.6%) of them had multiple lesions including 37% malignant gliomas, 15% primary lymphoma, 15% brain metastases, 12% low grade gliomas, 10% infectious disease (including brain abscess and viral multifocal encephalitis) and 6% ischemic lesions, and others had rare lesions.^[16] In the study of Calisaneller *et al.*, from 100 stereotactic biopsies, 4.25% of the cases were multiple^[10]

In the analysis of Shahzadi *et al.*, 7.6% (22 of 288 cases) of thalamic lesion biopsies showed bilateral lesions, and in the study of Zali *et al.*, 67% of ($n = 90$) cerebral lymphoma biopsies, revealed multiple lesions.^[17,18]

In our study, 10.1% of sampled lesions were multiple and the histologic diagnoses, according to their prevalence, were as following: Grade II astrocytoma, grade I astrocytoma, glioblastoma multiform, grade III astrocytoma, malignant lymphoma, metastases [Figure 1], astrocytoma pilocytic, abscess, craniopharyngioma, Vascular lesions (angiopathy), [Figure 2],

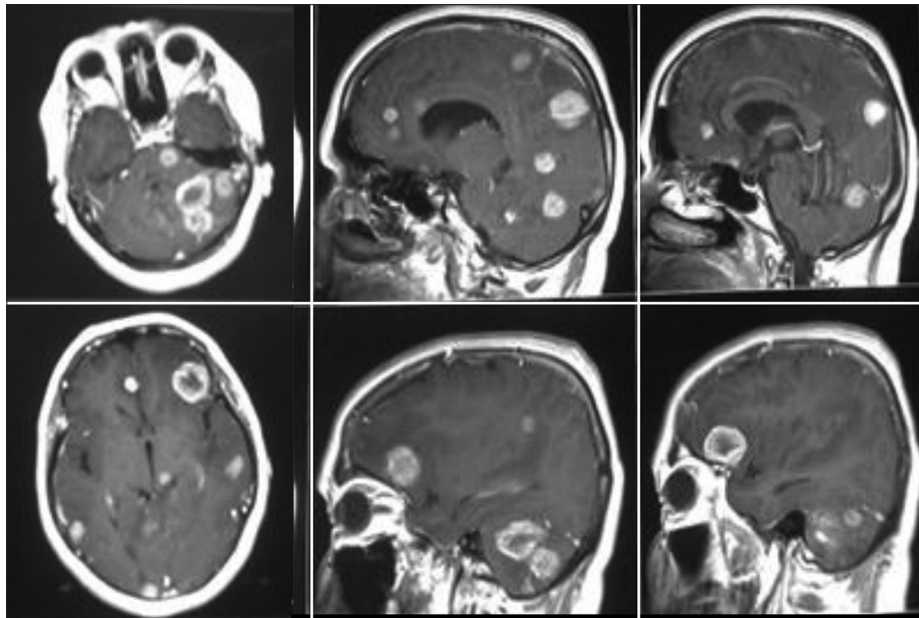


Figure 1: Metastatic adenocarcinoma (case 1)

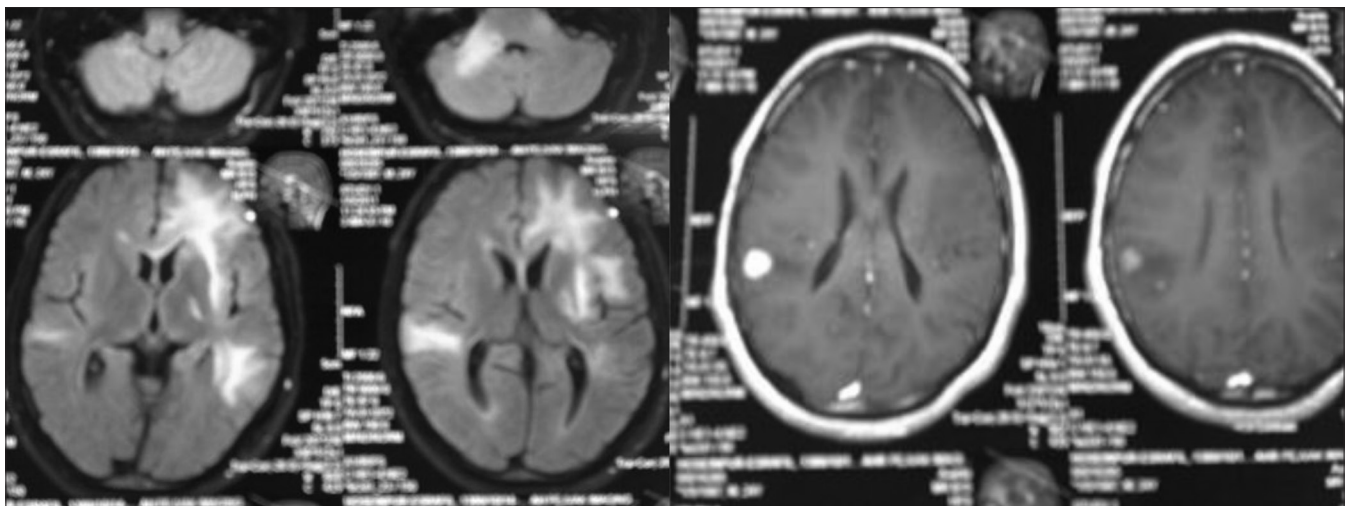


Figure 2: Hemorrhagic locococephalopathy (Vascular lesions (angiopathy)) (case 2)

tuberculosis and very rare cases of multiple sclerosis [Figure 3] and Systemic juvenile xanthogranuloma [Figure 4].

Authors reported multiple cranial lesions ($n = 7$) in 172 pediatric cases with intracranial lesions who underwent stereotactic biopsy,^[19] and in other study we reported a case of systemic juvenile xanthogranuloma with multiple central nervous system lesions [Figure 4].^[20] Furthermore, in a study about stereotactic biopsy of brain stem lesions we reported a large number of patients with multiple lesions involving brain stem that histopathologic examinations revealed glioblastoma multiform anaplastic astrocytoma, lymphoma, abscess, adenocarcinoma, and multiple sclerosis.^[21]

Therefore, patients with multiple cerebral space-occupying lesions can be categorized into two groups:

- A. Patients without previous history of tumor who had multiple SOLs: These patients should be analyzed thoroughly since, they are suspected to have malignancy in other parts of their bodies. However, screening is a time consuming process and missing the primary tumor is not unusual. Furthermore, previous immunosuppressive treatments (e.g., transplant recipients) or immune deficiency syndromes (e.g., AIDS) could lead to opportunistic infections in the brain (e.g., Aspergillus, Toxoplasmosis) or even secondary brain tumors (malignant lymphoma). Furthermore, lesions that are permitted to be treated rarely by open surgery, since, they are multiple, are preferable not to be treated with surgery. Then, stereotactic biopsy of one or two of these lesions should be conducted, in order to help oncologists to know the tissue properties of lesion (e.g., Squamous

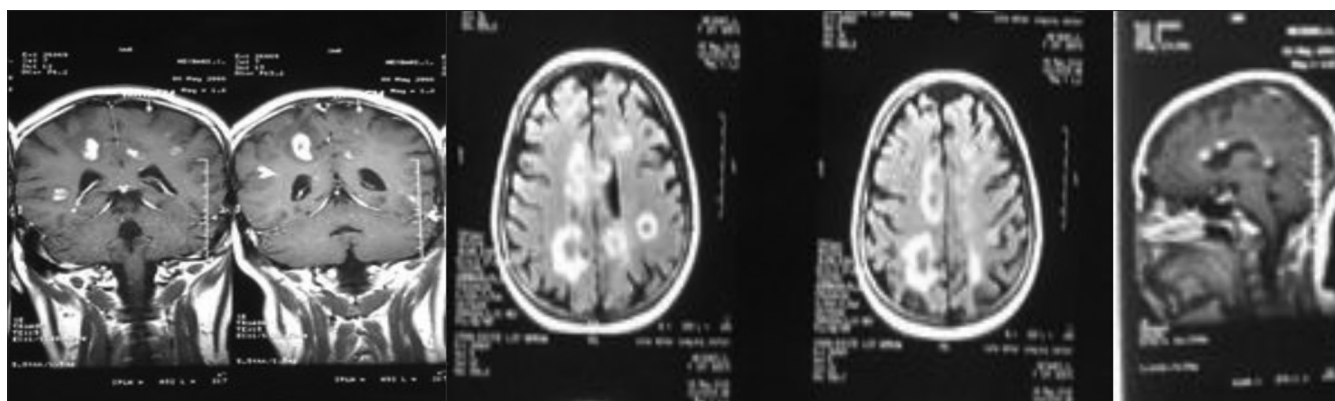


Figure 3: Multiple sclerosis (case 3)

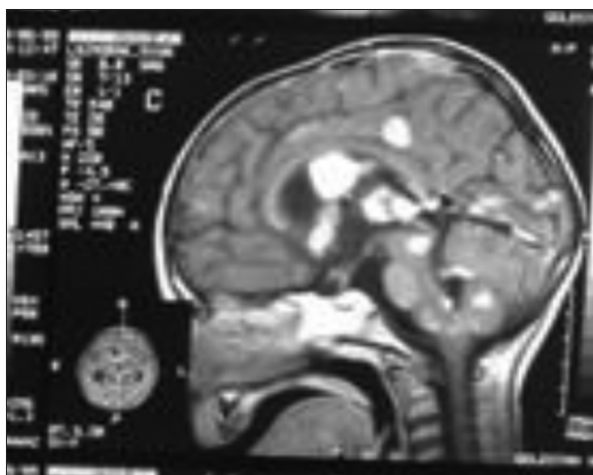


Figure 4: Systemic juvenile xanthogranuloma (case 4)

cell carcinoma, Adenocarcinoma, and lymphoma). At the same time, microbiologic studies begin in order to diagnose possible infectious diseases

- B. Patients with known primary tumor in other parts of their bodies and multiple cerebral SOLs without another metastatic spread. Any further, therapy must be decided based on of patient's condition and features of the primary tumor. If the usefulness of radiotherapy, chemotherapy, or both be considered, metastases should be confirmed histologically because of decision making difficulty for both patient and doctor. However, as it mentioned before, diagnosed SOLs could have non-tumoral nature. Differentiation between metastatic and non-neoplastic tissues can be easily obtained by stereotactic biopsy which is a relative indication in these conditions.

Conclusions

Multiple cerebral lesions can face any surgeon with a serious problem. First, it is important to be assured that these lesions are tumors not inflammatory foci (such as multiple sclerosis and acquired immune deficiency syndrome). Secondly, it seems that the absence of a known tumor out of the brain is an

indication to get at least one tissue diagnosis, even when a tumor could be resected with craniotomy. Biopsy is suggested as a first step, which helps patients to overcome their mental stress, and it also make it possible to design the next therapy area (eventually surgery). When multiple tumors in a patient with primary tumor are being diagnosed, the value of biopsy is highly dependent on history and prognosis. If the possibility of definite cure is desirable and if the intracranial metastases will change the consequent treatment regimen, then biopsy could have an enormous importance.

References


1. von Campe G, Moschopoulos M, Hefti M. 5-Aminolevulinic acid-induced protoporphyrin IX fluorescence as immediate intraoperative indicator to improve the safety of malignant or high-grade brain tumor diagnosis in frameless stereotactic biopsies. *Acta Neurochir (Wien)* 2012;154:585-8.
2. Lucchinetti CF, Popescu BF, Bunyan RF, Moll NM, Roemer SF, Lassmann H, *et al.* Inflammatory cortical demyelination in early multiple sclerosis. *N Engl J Med* 2011;365:2188-97.
3. Borbély K. Functional imaging in brain tumors. *Orv Hetil* 2004;145:411-23.
4. Yamada K, Goto S, Kochi M, Ushio Y. Stereotactic biopsy for multifocal, diffuse, and deep-seated brain tumors using Leksell's system. *J Clin Neurosci* 2004;11:263-7.
5. Hu LS, Baxter LC, Smith KA, Feuerstein BG, Karis JP, Eschbacher JM, *et al.* Relative cerebral blood volume values to differentiate high-grade glioma recurrence from posttreatment radiation effect: Direct correlation between image-guided tissue histopathology and localized dynamic susceptibility-weighted contrast-enhanced perfusion MR imaging measurements. *AJNR Am J Neuroradiol* 2009;30:552-8.
6. Jawahar A, Weilbaecher C, Shorter C, Stout N, Nanda A. Multicentric glioblastoma multiforme determined by positron emission tomography: A case report. *Clin Neurol Neurosurg* 2003;106:38-40.
7. Schmierer K, Scaravilli F, Altmann DR, Barker GJ, Miller DH. Magnetization transfer ratio and myelin in post-mortem multiple sclerosis brain. *Ann Neurol* 2004;56:407-15.
8. Uchino M, Kitajima S, Miyazaki C, Otsuka T, Seiki Y, Shibata I. Peritumoral hemorrhage immediately after radiosurgery for metastatic brain tumor. *No Shinkei Geka* 2003;31:911-6.
9. Utsuki S, Oka H, Tanizaki Y, Kondo K, Kawano N, Fujii K. Pathological features of intracranial germinomas with reference to fibrous tissue and granulomatous change. *Brain Tumor Pathol* 2005;22:9-13.
10. Calişaneller T, Ozdemir O, Ozger O, Ozen O, Kiyici H, Caner H, *et al.* The accuracy and diagnostic yield of computerized tomography guided stereotactic biopsy in brain lesions. *Turk Neurosurg* 2008;18:17-22.
11. Dammers R, Haitsma IK, Schouten JW, Kros JM, Avezaat CJ,

Meshkini, *et al.*: Stereotactic biopsy in multiple brain lesions

- Vincent AJ. Safety and efficacy of frameless and frame-based intracranial biopsy techniques. *Acta Neurochir (Wien)* 2008;150:23-9.
12. Jain D, Sharma MC, Sarkar C, Deb P, Gupta D, Mahapatra AK. Correlation of diagnostic yield of stereotactic brain biopsy with number of biopsy bits and site of the lesion. *Brain Tumor Pathol* 2006;23:71-5.
 13. Kimura A, Ueyama H, Kimura N, Fujimoto S, Kumamoto T. Progressive multifocal leukoencephalopathy in an HTLV-I carrier. *Clin Neurol Neurosurg* 2006;108:768-71.
 14. Paleologos TS, Dorward NL, Wadley JP, Thomas DG. Clinical validation of true frameless stereotactic biopsy: Analysis of the first 125 consecutive cases. *Neurosurgery* 2001;49:830-5.
 15. Schmierer K, Scaravilli F, Barker GJ, Gordon R, MacManus DG, Miller DH. Stereotactic co-registration of magnetic resonance imaging and histopathology in post-mortem multiple sclerosis brain. *Neuropathol Appl Neurobiol* 2003;29:596-601.
 16. Franzini A, Leocata F, Giorgi C, Allegranza A, Servello D, Broggi G. Role of stereotactic biopsy in multifocal brain lesions: Considerations on 100 consecutive cases. *J Neurol Neurosurg Psychiatry* 1994;57:957-60.
 17. Shahzadi S, Andalibi R, Sharifi G. Biopsy of thalamic lesions using computed imaging-assisted stereotaxis: Report of 15 years of experiences. *Arch Iran Med* 2005;8:188-91.
 18. Zali A, Shahzadi S, Mohammad-Mohammadi A, Taherzadeh K, Parsa K. Cerebral lymphoma: Clinical and radiological findings in 90 cases. *Arch Iran Med* 2007;10:194-8.
 19. Meshkini A, Shahzadi S, Zali A, Parsa K, Afrough A, Hamdi A. Computed tomography-guided stereotactic biopsy of intracranial lesions in pediatric patients. *Childs Nerv Syst* 2011;27:2145-8.
 20. Meshkini A, Shahzadi S, Zali A, Tajeddini A, Mirzayan J, Hamdi A. Systemic juvenile xanthogranuloma with multiple central nervous system lesions. *J Cancer Res Ther* 2012;8:311-3.
 21. Meshkini A, Shahzadi S, Zali A, Parsa K, Afrough A, Hamdi A. Stereotactic computed tomography-guided biopsy of brainstem lesions. *Neurosurg Q* 2012;22:137-40.

How to cite this article: Meshkini A, Shahzadi S, Alikhah H, Naghavi-Behzad M. Role of stereotactic biopsy in histological diagnosis of multiple brain lesions. *Asian J Neurosurg* 2013;8:69-73.

Source of Support: Nil, **Conflict of Interest:** None declared.



Announcement

Android App



Download
**Android
application**

FREE

A free application to browse and search the journal's content is now available for Android based mobiles and devices. The application provides "Table of Contents" of the latest issues, which are stored on the device for future offline browsing. Internet connection is required to access the back issues and search facility. The application is compatible with all the versions of Android. The application can be downloaded from <https://market.android.com/details?id=comm.app.medknow>. For suggestions and comments do write back to us.